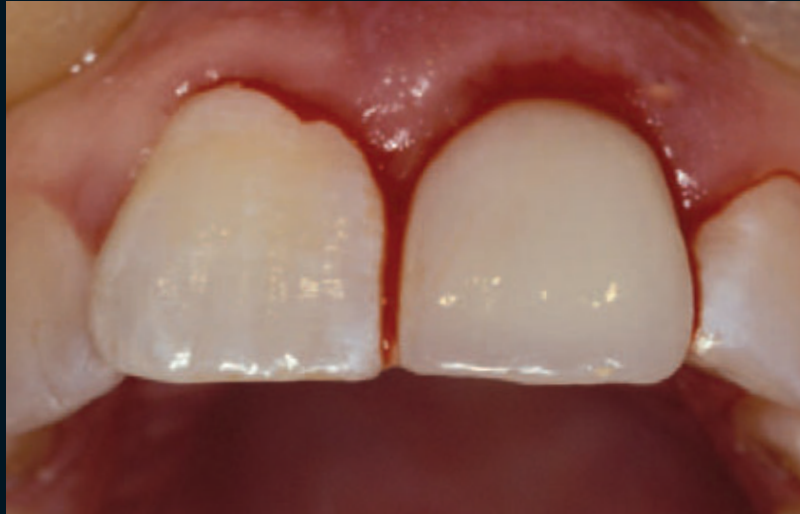

# CONTEMPORARY IMPLANT CONCEPTS IN AESTHETIC DENTISTRY — PART 2: IMMEDIATE SINGLE-TOOTH IMPLANTS

Tidu Mankoo, BDS\*



*Immediate implant placement and provisionalization in the aesthetic region has demonstrated predictable long-term results. Use of the immediate loading protocol significantly reduces the need for a second surgical intervention following implant placement. Based on the patient's preoperative condition, this technique can also be incorporated in select cases without the need for complicated bone grafting and augmentation procedures in compromised ridges. This article discusses the placement of single-tooth implants in the anterior region and presents the advantages and limitations of the immediate placement protocol.*

#### Learning Objectives:

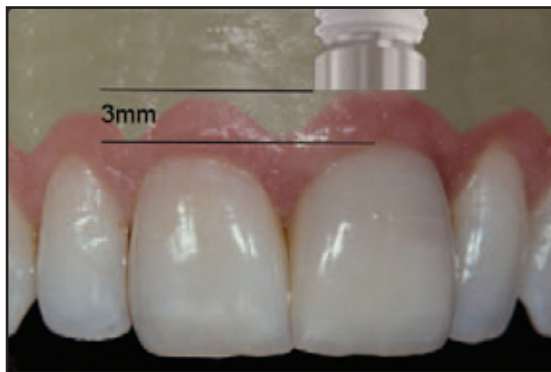
This article presents the considerations associated with immediate implant placement and provisionalization in the aesthetic zone. Upon reading this article, the reader should:

- Identify the advantages and limitations of immediate implant loading.
- Be aware of the considerations that must be addressed when attempting a flapless implant placement approach.

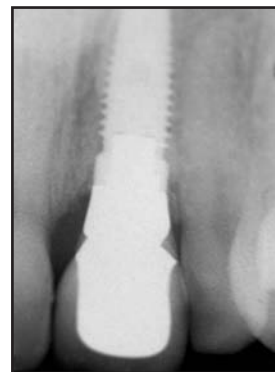*Key Words: implant, immediate, provisionalization, aesthetics, osseointegration*

\*Private practice, Windsor, United Kingdom.

Tidu Mankoo, BDS, Dorset House, 1 Dorset Road, Windsor, Berks, UK SL4 3BA  
Tel: +44-0-1753-833-755 • Fax: +44-0-1753-830-477 • E-mail: info@mankoo.co.uk



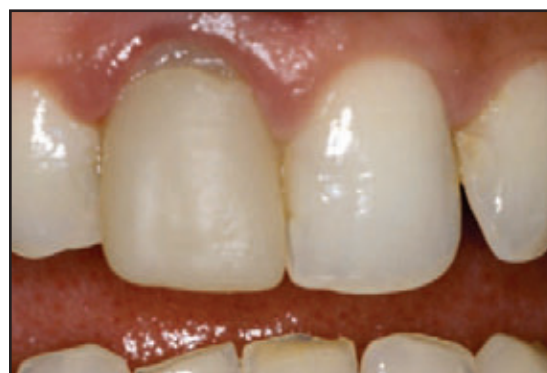**Figure 1.** Implant placement illustrated 3 mm apical from the desired labial gingival margin to facilitate a smooth transition from the diameter of the fixture to the cervical tooth form of the restoration.



**Figure 2.** Radiograph 2 years following restoration of a central incisor with an immediate implant system. The tapered implant demonstrated similar contours as compared to natural teeth.

Immediate implant placement and provisionalization have demonstrated increased predictability and applicability in clinical practice.<sup>1-6</sup> The use of immediate implant loading protocols allows the clinician to reduce the need for surgical intervention as well as complicated bone grafting and augmentation procedures required to rebuild resorbed or previously edentulous ridges. Although the bulk of the dental literature to date has related to immediate implant treatment carried out with a two-stage approach,<sup>7,12</sup> the one-stage technique is gaining popularity.<sup>3,5,13-17</sup>

This one-stage approach has the advantage of a simplified surgical approach and eliminates the need for a second surgery to uncover the implant. After 10 years of experience in the evolution of this technique, the author has observed a significant improvement in the patient's postoperative experience following the use of a flapless approach for access to the implantation site. Even when a flapless approach is not possible (ie, where significant bone augmentation and grafting is required), a flap can be raised, and necessary grafting can be performed at the time of tooth extraction and implant placement. While the benefit of the reduced surgical trauma is eliminated following flap elevation, the treatment period may be reduced by immediate implant placement. In addition, implant placement into a fresh extraction site provides an adequate supply of blood to the wound and allows sufficient bone maintenance since resorption and remodeling will not yet have occurred. In this latter situation, implant placement can also be performed using a one- or two-stage approach, depending on the circumstances and



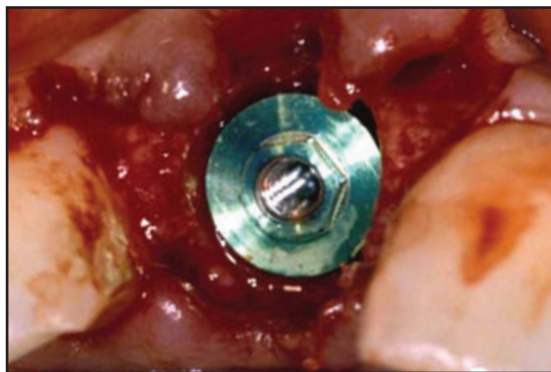
**Figure 3.** Case 1. Preoperative appearance demonstrated compromised gingival levels.

the clinician's preference. Soft tissue augmentation can also be completed, or socket seal surgery can be performed if required.

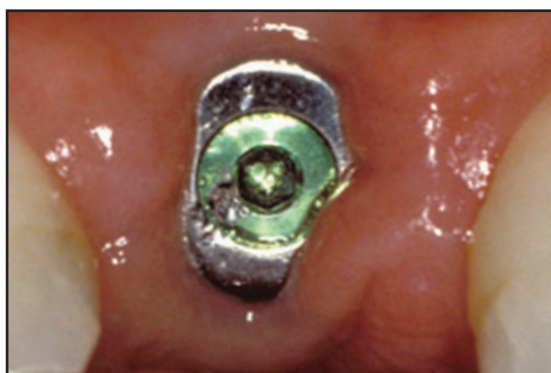### The Flapless Approach

Soft tissue healing and maturation can occur simultaneously with implant integration when a flapless, one-stage approach is used. Favorable maintenance of the soft tissue contours, particularly the interdental papilla, has also been observed using this technique. This benefit may be associated with the immediate gingival support provided by the provisional restoration or healing abutment.

As with traditional implant treatment, however, approximately 1 mm of gingival recession may occur at the labial gingival level following placement of the definitive restoration,<sup>18,19</sup> which may be attributed to the biologic width formation following repeated removal and replacement of the implant components during impression-making, try-in, and fitting of the restoration.<sup>20,21</sup> This

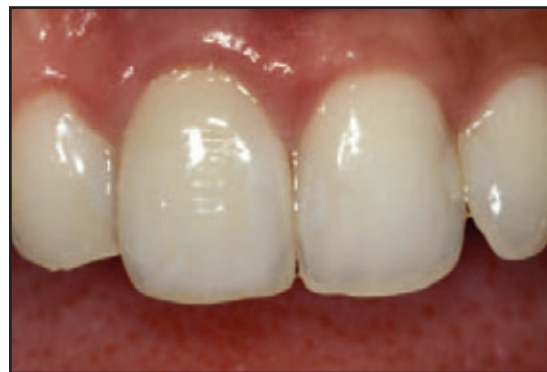

**Figure 4.** Immediate implant placement was positioned close to the labial plate. A flap was also unnecessarily raised. Adequate interproximal bone height was essential for the maintenance of interdental papillae.



**Figure 5.** Intraoral evaluation following six months of healing demonstrated abundant tissue volume in the papilla areas.

apical movement of the biologic width complex generally leads to a corresponding labial recession of approximately 1 mm.<sup>22</sup> Care must, therefore, be taken when an immediate single-tooth implant restoration is planned in the anterior region. Many clinicians opt to utilize a delayed implant placement approach in the aesthetic zone in order to overbuild the soft tissue to allow for the anticipated recession.



**Figure 6.** Postoperative appearance of the definitive PFM crown restoration demonstrated acceptable aesthetics. Complete restoration of gingival form was created by the proper tooth contours.

In the author's experience, however, this recession can be managed successfully following a slight modification of the surgical technique. While careful attention to detail is required during the restoration of a central incisor in a patient with a high lip line and thin, high, scalloped tissue, the author suggests the use of an immediate implant approach combined with simultaneous placement of a connective tissue graft. The graft can be placed between the labial gingival tissue margin and the implant healing abutment or abutment/provisional crown to create thicker tissue and maintain a more stable gingival level. This technique has been well established for predictable root coverage and ridge augmentation procedures around teeth, and the author has found the technique similarly useful around dental implants. Care must be taken when diagnosing the patient and creating a treatment plan based on a flapless approach versus traditional flap elevation (Table).

The interproximal bone level of the adjacent teeth is an essential diagnostic factor. The apical extension of the contact area between the implant crown and

**Table**

***The Flapless Approach Versus Flap Elevation***

**Flapless Surgery**

Minimal bone grafting required for small defects only  
Adequate soft tissue  
No large bone defects  
Tapered implant  
Single-stage placement  
Immediate provisionalization

**Flap Elevation**

Bone graft required  
Large bone defects  
Inadequate soft tissue  
Straight or tapered implant  
One- or two-stage placement  
Provisional FPD or denture

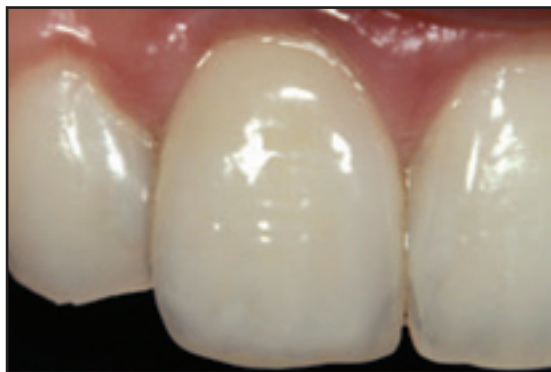

Figure 7. Postoperative appearance demonstrated gingival healing 3 months following final crown placement.

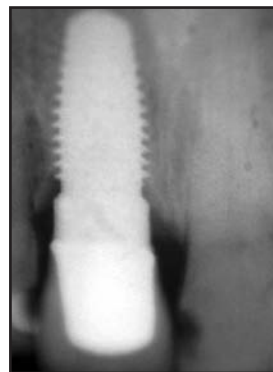


Figure 8. Postoperative radiograph following 2 years of function demonstrated continued healing and complete osseointegration.

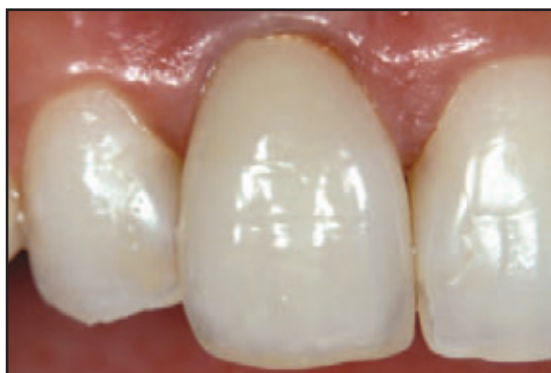

Figure 9. Approximately 1 mm of gingival recession was evident following 2 years of function due to the excess width of the fixture and the proximity of the implant to the labial bone plate.

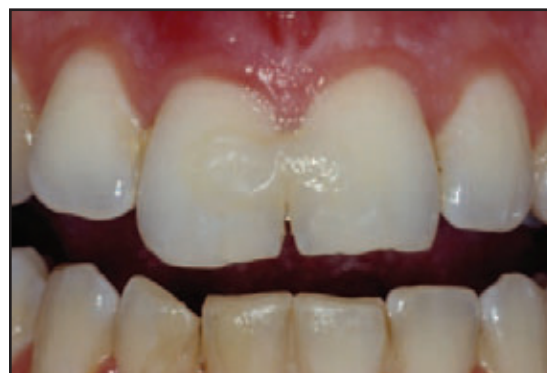

Figure 10. Case 2. Preoperative view following fracture in the maxillary anterior region.

adjacent tooth must be 5 mm or less from the interdental bone level for predictable papilla development.<sup>23</sup> The patient's gingival phenotype will further influence treatment planning. For example, labial recession is less likely in patients with thick, flat gingival tissues than those with a high scallop and thin tissues. The aforementioned "sandwich" connective tissue graft creates a more stable result and can be employed with a conventionally positioned flap once the definitive restoration is placed. It is the author's preference, however, to perform bone augmentation at the time of tooth extraction and implant placement wherever possible, thus avoiding the need for secondary surgical intervention.

The use of this immediate flapless approach with either a healing abutment or provisional implant restoration appears to provide a minimally invasive, reliable solution. While orthodontic extrusion of the tooth or root remnant prior to extraction may further address the potential aesthetic compromise that may be created by the

anticipated 1 mm of gingival recession, this option is not possible in the vast majority of cases, since many single-tooth cases are fractured or failed post crowns where root fracture or infection necessitate immediate extraction. In addition, given today's possibilities for soft tissue and bone augmentation, it is questionable whether it is even necessary at all. The choice of approach ultimately resides with the individual clinician and will be influenced by his or her experience, ability and preference. In the author's practice, an immediate flapless approach is now the treatment of choice wherever possible. Careful patient selection, diagnosis, and treatment planning remain cornerstones in optimizing the aesthetic outcome of treatment.

The benefit of the reduced surgical trauma associated with the immediate flapless approach, as well as the possibility of an immediate provisional crown where there is adequate primary fixation, represent additional patient benefits. The patient generally experiences

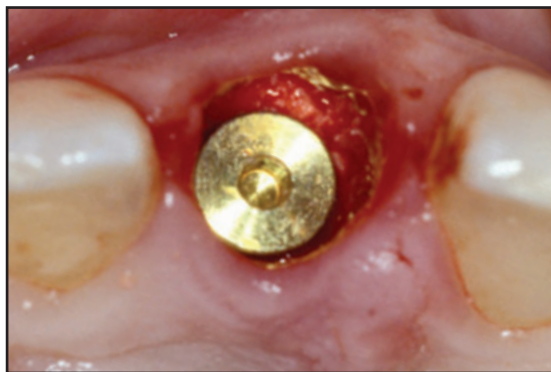

Figure 11. An HA-coated implant was placed 4 mm from the existing gingival levels and a graft material was placed into the labial void with the cover screw in place to further support the labial bone and tissue.

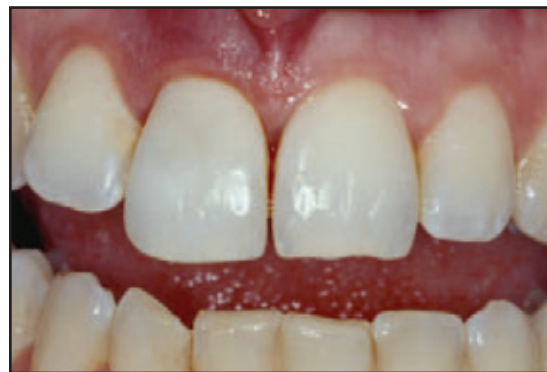

Figure 12. The patient's tooth was adapted to the prepared abutment and cemented in place.

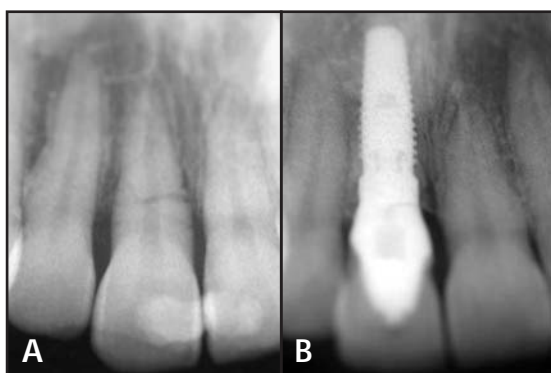


Figure 13A. Preoperative radiograph of the fractured incisor. 13B. Postoperative radiograph 1 year following restoration demonstrated crown adaptation and maintenance of the bone levels around the implant.

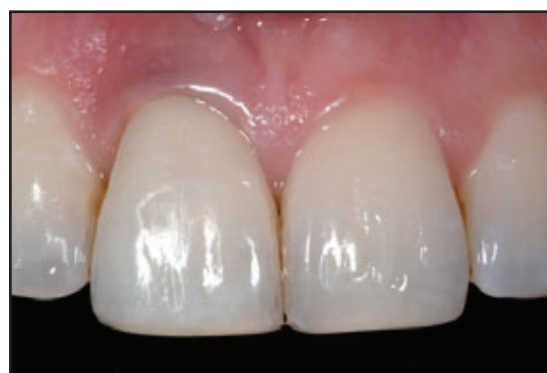

Figure 14. Postoperative clinical appearance following 1 year of function. Additional incisal re-contouring was performed to improve the tooth form. The titanium abutment creates some greying of the soft tissues.

minimal postoperative pain, minimal swelling, and the psychological impact of tooth removal seems to be significantly alleviated by the clinician's ability to immediately replace the tooth. Maintenance of the interdental soft tissue architecture can also be facilitated when using an immediate approach. While an equivalent result can be achieved using a conventional delayed approach if the bone architecture is appropriate, the treatment period, number of surgical invasions, and complexity of the required surgical procedures are reduced.

### Implant Selection

The author's preference is to utilize a tapered implant for immediate placement cases due to its ability to better approximate the socket shape and obtain excellent primary stability due to its "self-tightening" nature. This design also allows for a gradual increase of the implant width for the development of transgingival contours of the abutment crown complex that are similar to the tooth

(Figures 1 and 2). The implant head should be ideally placed approximately 2 mm to 3 mm apical from the desired final labial gingival margin.<sup>24,25</sup> The implant osteotomy should be prepared towards the palatal aspect of the socket and extend 3 mm apically beyond the socket or any periapical lesion into sound bone.<sup>7</sup>

### Considerations During Immediate Single-Tooth Implant Replacement

Immediate single-tooth implants can now be managed with increased predictability. The concept of the biologic width further maximizes the aesthetic outcomes of such restorations (Table).<sup>26</sup> In immediate single-tooth implants, it is important for the implant to be placed towards the palatal aspect of the extraction socket, and too wide an implant should be avoided (Figures 3 through 9) since:

- This does not allow for sufficient space between the implant and the labial bone, which will then fall within the horizontal component of the

three-dimensional biologic width or space (up to 1.5 mm) and be resorbed;

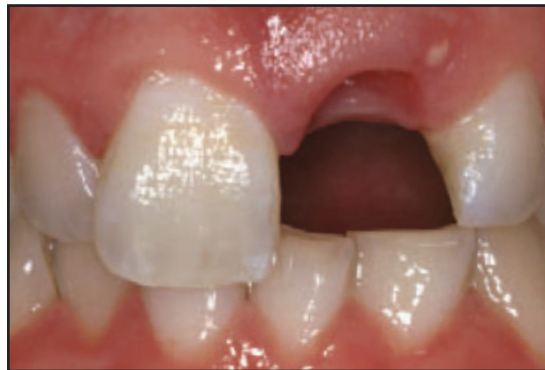- Excessive implant width limits the development of an appropriate labial subgingival and transgingival contour. Once the abutment and the restoration are fabricated, the contours may be too bulky or labially placed, which can lead to labial recession;
- The labial bone may be too thin to cope with occlusal stresses;
- Raising a flap compromises the blood supply to the thin labial bone; and
- An implant with excessive width may leave insufficient space for proper nutrition of the labial bone.

It was traditionally hypothesized that the placement of a space between the implant and socket may lead to ingress of soft tissue and prevent proper osseointegration, which caused many clinicians to place graft materials to fill the gap. Recent research, however, indicates that this space may not be of such concern.<sup>27</sup> In fact, a 1-mm to 1.5-mm gap may be ideal to maintain the labial bone and implant width and position should, therefore, be selected with this parameter in mind.

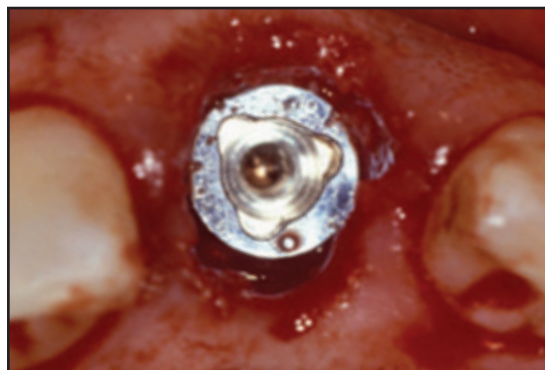
### Case Presentations

#### **Immediate Implant Placement and Direct Provisionalization**

A 23-year-old female patient presented for restoration of the fractured maxillary right central incisor (Figure 10). A high lip line and pronounced gingival scallop were evident. The gingival margin of tooth #8(11) was slightly extruded and positioned approximately 1 mm more coronal than tooth #9(21). A provisional composite splint had been previously positioned. The fractured incisor was carefully removed with the periosteal elevator and forceps, ensuring minimal trauma to the surrounding tissue and bone. Since the implant head had to be positioned 2 mm to 3 mm relative to the desired final level of the gingival margin once the definitive restoration was placed, care was taken to ensure that the implant was positioned slightly deeper than normal (ie, 4 mm from the preoperative gingival margins) to allow for the anticipated 1 mm to 2 mm of gingival recession (Figure 11). A nonresorbable allograft material (Bio-Oss, Osteohealth, Shirley, NY) was placed with the implant cover screw in place. This material was used to help preserve the bony architecture and maintain the definitive gingival contours.



**Figure 15. Case 3. Preoperative facial appearance following fracture of the maxillary left central incisor.**



**Figure 16. The implant head was placed 3 mm apical to the gingival margin and labial void was packed with non-resorbable bone allograft.**

The crown section of the removed tooth was hollowed out, and a cement vent hole was prepared in the cingulum area. The tooth was adapted to a prepared angled abutment. The internal aspect of the tooth and margins were etched, and a dentin bonding agent was placed and light-cured. The abutment and tooth were then placed on the implant and relined. The crown and abutment were then removed once again, and the margins were refined with a flowable composite. The margins were polished, the internal fit surface was slightly relieved to create a space for the luting cement, and the vent hole was checked for patency. This procedure prevented apical extrusion of the cement into the socket. The abutment was tightened, and the access hole was sealed with a cotton pledget and a provisional filling material. The tooth fragment was then used as a provisional crown and cemented. Excess cement was carefully removed using a thin probe around the crown and subgingival regions (Figure 12). The incisal edges of the central incisors were slightly modified for improved symmetry.

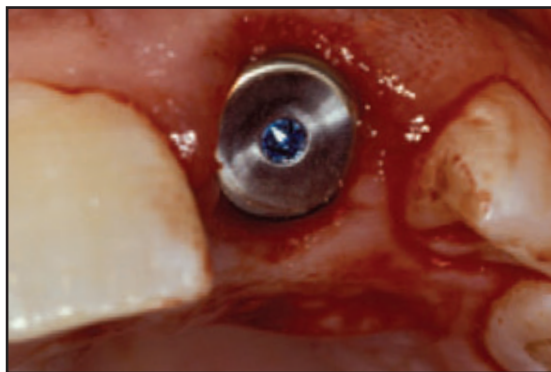


Figure 17. The healing abutment was positioned with space left to be filled by the relined pontic.

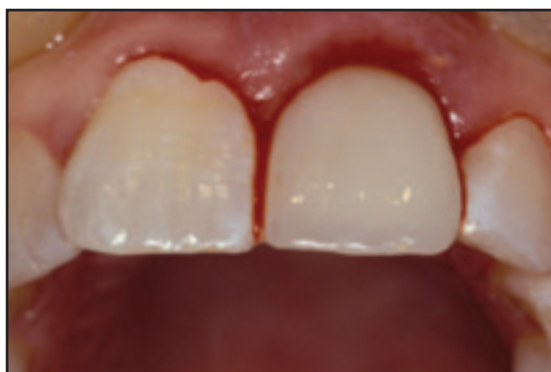

Figure 18. An adhesive provisional FPD with a hollow pontic was positioned during surgery. The pontic was adapted to provide appropriate support to the labial and interproximal gingival tissues.

The provisional fragment was recontoured and used for 1 year as a long-term provisional restoration (Figures 13 and 14). Although the titanium abutment was apparent through the tissues, contemporary technologies would allow the use of a ceramic abutment that could alleviate the darkened appearance. Since the natural prosthesis demonstrated satisfactory function and positioning, it was decided not to provide an alternative restoration.

### **Immediate Implant Placement and Provisionalization with FPD**

A 34-year-old male patient presented with a failed post-and-core crown restoration and root fracture in tooth #8 (Figure 15). The patient had a thick, flat gingival genotype with a low scallop. There was a small labial sinus and also a periapical area evident on the preoperative radiograph, so it was uncertain whether an immediate implant would be possible. A small Maryland-style provisional composite fixed partial denture (FPD) with a hollow pontic was fabricated prior to extraction. Careful extraction of the root

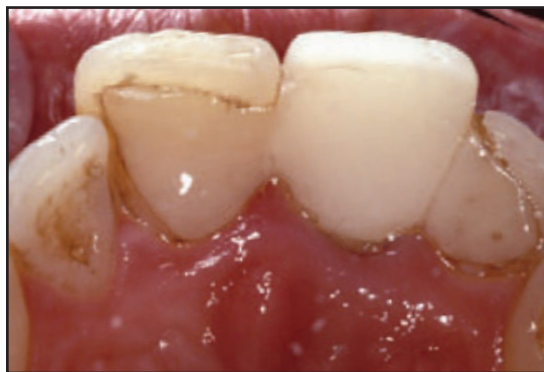

Figure 19. Palatal view of the provisional FPD 1 week postoperatively.

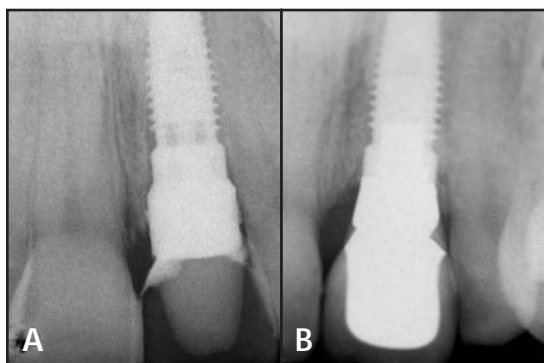
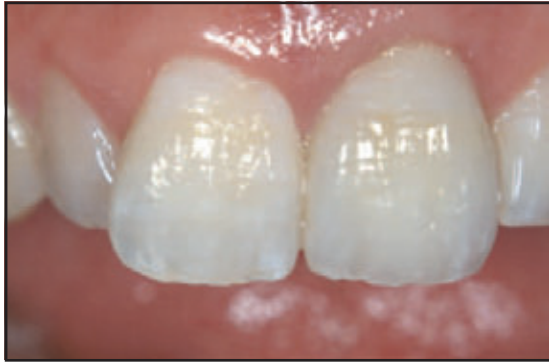

Figure 20A. Postoperative radiograph 1 week following implant placement. 20B. Postoperative radiograph 2 years following treatment demonstrates maintenance of the bone levels surrounding the implant

fragments was performed using a periosteal elevator and small forceps. The socket was examined and the labial bone found intact with a small fenestration approximately 2 mm to 3 mm from the coronal labial bone margin. The apical granuloma was chronic, encapsulated, and easily removed with the root. The socket was thoroughly debrided, and an implant osteotomy was prepared beyond the lesion into sound bone. A 5 mm × 13 mm tapered implant was placed 3 mm from the gingival margin.

The coronal diameter of the implant placed was slightly narrower than the actual socket (Figure 16) to allow for flexibility in the development of an optimum subgingival and transgingival contour and to allow space for the biologic width. A bone allograft material was firmly packed into the labial space between the implant and the labial bone to provide support for the labial gingival tissues and enable bone fill of the void and regeneration of the fenestrated bone. The remaining periosteum functioned as a membrane and helped promote bone healing. An appropriate healing abutment



**Figure 21. Appearance at 2 years after final restoration of PFM crown on a custom abutment with porcelain shoulder.**

was selected and positioned on the implant (Figure 17). The provisional FPD with a hollow pontic was relined onto the healing abutment and refined with flowable composite (Figure 18). The tooth form was carefully developed to provide support to the labial and interproximal tissues (Figures 19 and 20A). The FPD was cemented using a resin-modified glass-ionomer cement (eg, Fuji Plus or Fuji II LC, GC America, Alsip, IL; Vitremer, 3M Espe, St. Paul, MN). The pontic was luted to the healing abutment with a provisional cement. The definitive prosthesis demonstrated maintenance of the gingival margins, papillae, and surrounding bone 2 years postoperatively (Figures 20B and 21).

### Conclusion

While immediate placement offers significant clinical advantages when combined with a flapless single-stage approach or immediate provisionalization technique, careful consideration of the proximity of the implant surface to the bone and adjacent teeth is essential for success. A thorough understanding of the biologic width concept, as well as careful case selection and diagnosis, are essential in successful treatment planning. The provision of immediate support for the gingival tissue may also influence the stability and maintenance of the gingival contours and implant bone levels. The next article in this series will further discuss the immediate implant concept to include multiple adjacent implants.

### Acknowledgment

*The author declares no financial interest in any of the products cited herein. The author mentions his gratitude to Eva Forst and Nikki Cox for their contribution in the laboratory and technical aspects of the cases presented.*

### References

1. Tarnow DP, Emtiaz S, Classi A. Immediate loading of threaded implants at stage 1 surgery in edentulous arches: Ten consecutive case reports with 1- to 5-year data. *Int J Oral Maxillofac Impl* 1997;12(3):319-324.
2. Grunder U. Immediate functional loading of immediate implants in edentulous arches: Two-year results. *Int J Periodont Rest Dent* 2001;21(6):545-551.
3. Garber DA, Salama MA, Salama H. Immediate total tooth replacement. *Compend Cont Educ Dent* 2001;22(3):210-216,218.
4. Mankoo T. Evolving implant concepts in complex restorative challenges. *Quint Dent Technol* 2002:198-212.
5. Touati B, Guez G. Immediate implantation with provisionalization: From literature to clinical implications. *Pract Proced Aesthet Dent* 2002;14(9):699-707.
6. Degidi M, Piattelli A. Immediate functional and non-functional loading of dental implants: A 2- to 60-month follow-up study of 646 titanium implants. *J Periodontol* 2003;74(2):225-241.
7. Gelb DA. Immediate implant surgery: Three-year retrospective evaluation of 50 consecutive cases. *Int J Oral Maxillofac Impl* 1993;8(4):388-399.
8. Schwartz-Arad D, Chaushu G. The ways and wherefores of immediate placement of implants into fresh extraction sites: A literature review. *J Periodontol* 1997;68(10):915-923.
9. Fugazzotto PA, Shanaman R, Manos T, Shectman R. Guided bone regeneration around titanium implants: Report of the treatment of 1,503 sites with clinical reentries. *Int J Periodont Rest Dent* 1997;17(3):292-299.
10. Cosci F, Cosci B. A 7-year retrospective study of 423 immediate implants. *Compend Cont Educ Dent* 1997;18(9):940-942,944.
11. Grunder U, Polizzi G, Goene R, et al. A 3-year prospective multicenter follow-up report on the immediate and delayed-immediate placement of implants. *Int J Oral Maxillofac Impl* 1999;14(2):210-216.
12. Polizzi G, Grunder U, Goene R, et al. Immediate and delayed implant placement into extraction sockets: A 5-year report. *Clin Impl Dent Relat Res* 2000;2(2):93-99.
13. Bragger U, Hammerle CH, Lang NP. Immediate transmucosal implants using the principle of guided tissue regeneration (III). A cross-sectional study comparing the clinical outcome 1 year after immediate to standard implant placement. *Clin Oral Impl Res* 1996;7(3):268-276.
14. Wohrle PS. Single-tooth replacement in the aesthetic zone with immediate provisionalization: Fourteen consecutive case reports. *Pract Periodont Aesthet Dent* 1998;10(9):1107-1114.
15. Misch CE, Wang HL. Immediate occlusal loading for fixed prostheses in implant dentistry. *Dent Today* 2003 Aug;22(8):50-56.
16. Raghoebar GM, Friberg B, Grunert I, et al. 3-year prospective multicenter study on one-stage implant surgery and early loading in the edentulous mandible. *Clin Impl Dent Relat Res* 2003;5(1):39-46.
17. Misch CE, Degidi M. Five-year prospective study of immediate/early loading of fixed prostheses in completely edentulous jaws with a bone quality-based implant system. *Clin Impl Dent Relat Res* 2003;5(1):17-28.
18. Grunder U. Stability of the mucosal topography around single-tooth implants and adjacent teeth: 1-year results. *Int J Periodont Rest Dent* 2000;20(1):1-17.
19. Small PN, Tarnow DP. Gingival recession around implants: A 1-year longitudinal prospective study. *Int J Oral Maxillofac Impl* 2000;15(4):527-532.
20. Hermann JS, Buser D, Schenk RK, et al. Biologic width around titanium implants. A physiologically formed and stable dimension over time. *Clin Oral Impl Res* 2000;11(1):1-11.
21. Hermann JS, Buser D, Schenk RK, et al. Biologic Width around one- and two-piece titanium implants. *Clin Oral Impl Res* 2001;12(6):559-571.
22. Saadoun AP, LeGall M, Touati B. Selection and ideal tridimensional implant position for soft tissue aesthetics. *Pract Periodont Aesthet Dent* 1999;11(9):1063-1072.
23. Tarnow DP, Magner AV, Fletcher P. The effect of the distance from the contact point to the crest of bone on the presence or absence of the interproximal dental papilla. *J Periodontol* 1992;63(12):995-996.
24. Jovanovic SA, Paul SJ, Nishimura RD. Anterior implant-supported reconstructions: A surgical challenge. *Pract Periodont Aesthet Dent* 1999;11(5):551-558.
25. Kais JC, Kan JY. Predictable peri-implant gingival aesthetics: Surgical and prosthodontic rationales. *Pract Proced Aesthet Dent* 2001;13(9):691-698.
26. Mankoo T. Contemporary implant concepts in aesthetic dentistry—Part I: Biologic width. *Pract Proced Aesthet Dent* 2003;15(8):609-616.
27. Botticelli D, Berglundh T, Buser D, Lindhe J. The jumping distance revisited: An experimental study in the dog. *Clin Oral Impl Res* 2003;14(1):35-42.