

# Smiling in the Sky!

Imagine having to put your false teeth in a glass each night. Not so unusual if you're in your later years, but if you are a teenager, well that's a different story.



Sarah aged 14

SARAH'S TEETH AFFECTED HER IN SO MANY WAYS; for instance when it came to boys Sarah had little confidence and often felt jealous and insecure around her friend's 'normal' smiles. Meeting new people became a source of depression as Sarah's obsession with her looks took precedence.

Her low self-esteem meant that she struggled to establish herself in her chosen career. Having always dreamed of being an air-hostess, her dreams were shattered at her first interview with a major airline when she was introduced to the boss who casually said *"God! Are your teeth your own?"* She didn't get the job. Eventually after a successful application Sarah joined the first class long-haul cabin crew for British Airways. Sarah decided that she finally had to do something about her teeth, which is when she decided on cosmetic dentistry, *"I wish I had them done sooner. Its changed my life! I would encourage anybody to go for it, even if you have to save for a while. Your teeth are with you for a long time!"*



Sarah is all smiles today with her new teeth



*"The beauty of this case demonstrates how with the correct management and materials we can achieve excellent results with restorations on teeth and/or implants. Sarah now has a beautiful, natural and healthy smile which, with correct looking after, should last for many years to come!"*

says Dr. Tidu Mankoo from the Windsor Centre for Advanced Dentistry.



Windsor Centre for Advanced Dentistry's innovative aesthetic dental solutions offer revolutionary treatments that make long-lasting, natural-looking teeth a reality for us all.

[www.advanceddentistry.co.uk](http://www.advanceddentistry.co.uk)

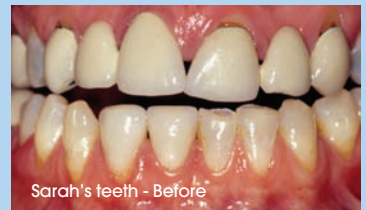The website presents all the in-depth knowledge for patients to be well equipped to understand what treatments are available to them.



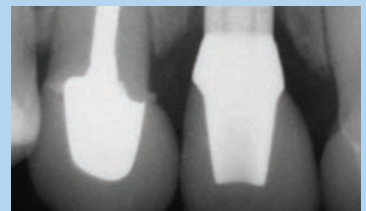
**WINDSOR CENTRE FOR  
ADVANCED DENTISTRY**

## THE SCIENCE

Sarah was missing her two lateral (outside upper incisors) and had old porcelain fused to metal bridges which were defective and looked unnatural. She also had some gum recession around the teeth and she had bone resorption where the lateral incisor teeth were missing, leaving the gum ridges with a sunken-in appearance. Dr. Tidu Mankoo, from the Windsor Centre for Advanced Dentistry, was able to restore her beautiful smile with some plastic gum microsurgery to bring back the gums, bone and gum regeneration to rebuild the edentulous gum ridges. Two implants placed to replace the missing upper lateral incisors with Procera® Zirconia abutments and these along with the upper incisors and canines were restored with six Procera® Alumina crowns. So altogether the upper front six teeth were restored creating a beautiful and yet completely natural-looking result.



Sarah's teeth - Before



Sarah's teeth - After